REPRODUCTIVE SYSTEM

Reproductive is the joint action of male and female reproductive system. Each system produces a gamete which carries the genetic material of the individual. Along with this, the female reproductive system has the additional responsibility of maintaining the embryo within it. Females are equipped to nourish the newborn babies by lactation. The male gamete is called spermatozoa and the female gamete is called ovum. The spermatozoa and the ova fused together to form the zygote and that begins the process of development of new individual.

SEX DIFFERENTIATION

Whether the zygote will develop into a male or a female is determined by the presence or absence of the Y chromosome in it. If the Y chromosome is present, the zygote develops into a male, if not it becomes a female. The presence of Y chromosome leads to development of testes and subsequent male characters. Absence of Y chromosome leads to development of a female automatically.

DEVELOPMENT OF REPRODUCTIVE SYSTEM:

In the embryo, at the start (6th week) the reproductive system is bi-potential that is either develop into a male or a female. This is composed of the primitive gonads containing a cortex and medulla, the Mullerian duct system and the Wolffian duct system. The external genitalia are also bi-potential up to eighth week. In the short arm of Y – chromosome is the sex determining gene (SRY gene) which cord for the testis determining factor (TDF). The TDF is responsible for the development of testis from the medulla of the primitive gonads. The testis now developed secretes testosterone from the Leydic cells under the influence of HCG and Mullerian inhibiting factor (MIF) from the sertoli cells. MIF causes regression of the mullerian system and the testosterone leads to development of Wolffian system into epididymis and vas deferns. Testosterone is also responsible for the development of male external genitalia.

When Y chromosome is absent there is no formation of TDF and the cortex of the primitive gonads develops into ovaries automatically. The embryonic ovaries need not secrete and the Mullerian system develops into Uterus and uterine tubes. The female genitalia also develop from the primitive genitalia automatically.

MALE REPRODUCTIVE SYSTEM

Male reproductive organs include the primary sex organs and accessory sex organs. Primary sex organs include a pair of testis and accessory sex organs are seminal vesicles, prostrate gland, urethra and penis.

TESTIS

Testis is the primary sex organ or gonad in males. They are 2 in number located in the sac- like structure called scrotum or scrotal sac. Scrotum is a small outpouching of the skin to the exterior of the body. It is divided into 2 by means of a median fissure formed by the layers of scrotum. Internally, it is divided into 2 compartments in each of which testis rests. This shows that the testis is located outside the body. Location of testis outside the body has an important function. The formation of sperms (spermatogenesis) requires a temperature lesser than the body temperature. The temperature within the scrotal sac is about 4°C lower than the body temperature. Thus the location of the testis outside the body in the scrotal sac provides a suitable environment for spermatogenesis. The testis is placed in the scrotal sac with the help of cremasteric muscle and dartos muscle. During cold temperature, the testes gets elevated with the help of these muscles towards the abdominal wall to keep it warm. During hot temperature, the testes descend to the scrotal sac. The inability of the testes to descend into the scrotal sac is called Cryptorchidism.

Coverings of testis:

Each testis is enclosed by 3 coverings

1. Tunica vasculosa- innermost covering made up of connective tissue rich in blood vessels.
2. Tunica albuginea- middle covering forming a dense fibrous capsule.
3. Tunica vaginalis- outermost closed cleft like covering formed by visceral and parietal layers which glide over one another thereby helping in free movement of testis.

The tunica albuginea radiate into the testis dividing its interior into numerous lobules. Each testis has about 200- 300 lobules. Each lobule contains 1- 4 coiled tubules called seminiferous tubules which forms the first part of duct system of male reproductive system.

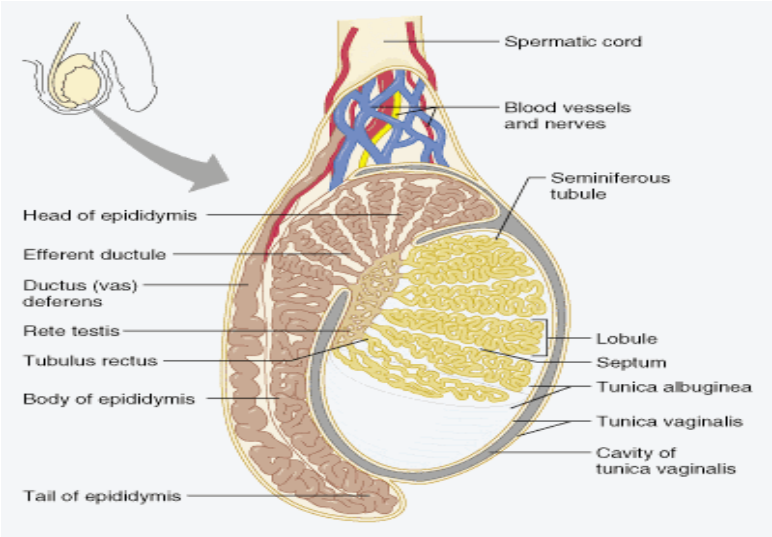

Towards the apex of each seminiferous lobule, the convoluted tubules unite to form a narrow

straight tubule which later joins with other tubules to form a network of thin- walled channels called rete testis.

From rete testis, 8- 15 tubules called vas efferens arises which join together to form the head of epididymis and then converge to form the duct of epididymis. Duct of epididymis is an enormously convoluted tubule with a length of about 4ms. At the end, the epididymis turns sharply upon itself and forms the vas deferens which later joins with urethra to form the genital tract. Epididymis is the site of sperm maturation, the process by which sperms acquire motility and ability to fertilize an ovum.

There are 2 types of cells within the seminiferous tubules- Germ cells and Sertoli cells. Germ cells or spermatogenic cells are the precursor cells of spermatozoa lying in between the sertoli cells arranged in an orderly manner. The germ cells occupy the spaces between th4e basement membrane and lumen of seminiferous tubules.

In children, the testis is not fully developed. So only the primitive germ cells called spermatogonia are present. With the onset of puberty, the spermatogenic cells are represented in all stages of differentiation.

Different stages of spermatogenic cells seen from periphery to lumen of seminiferous tubules are- Spermatogonium, primary spermatocyte, secondary spermatocyte and spermatid.

Sertoli cells are the supporting cells which provide support, protection and nourishment for spermatogenic cells present in seminiferous tubules. Sertoli cells are also called sustentacular cells or nurse cells. The spermatogenic cells present in seminiferous tubules are attached to sertoli cells by means of cytoplasmic connection. This attachment between germ cells and sertoli cells exists till the matured spermatozoa are released into the lumen of seminiferous tubules.

Functions of Sertoli cells:

1. Provide environment for development and maturation of spermatogenic cells.
2. Support and nourish the spermatogenic cells till the spermatozoa are released from them.
3. Enzyme aromatase present in sertoli cells convert androgens to estrogen.
4. Secrete Androgen Binding Protein (ABP) essential for testosterons activity particularly in spermatogenesis.
5. Secretes inhibin which inhibits the release of FSH form anterior pituitary.
6. Secrete activin which increases FSH release.
7. Secrete Mullerian Regression Factor (MRF) which is responsible for the regression of Mullerian duct during sex differentiation in fetus.

ACCESSORY SEX ORGANS

1. SEMINAL VESICLES- Are situated on either side of the prostate gland. Secretions of seminal vesicles are emptied into ampulla of vas deferens. The ampulla of vas deferens is continued as ejaculatory duct which passes through prostrate to form internal urethra.
2. PROSTATE GLAND- Is constituted by many secretory glands. Secretion of these glands is emptied into the internal urethra.
3. URETHRA- has 3 parts namely- prostrate urethra, spongy urethra and membranous urethra. Prostrate urethra is a continuation of the ejaculatory duct. Urethra contains mucus glands throughout its length which secretes mucus. A pair of bulbourethral glands is also present on either sides of urethra. It is also called Cowper's glands.
4. PENIS- is the male genital and copulatory organ (organ for sexual intercourse). Urethra passes through penis and opens to the exterior. Penis is formed by 3 erectile tissue masses, i.e., a pair of corpora cavernosa and unpaired corpus spongiosum. The corpus spongiosum surrounds the urethra and terminates distally to form glans penis. The erectile tissues are richly supplied with blood vessels. The erection of penis during sexual intercourse is the engorgement of these erectile tissues with blood. The covering of glans is called Prepuce or foreskin.

Blood- testis barrier

Blood- testis barrier is a mechanical barrier that separates blood from seminiferous tubules of the testes. It is formed by tight junctions between the adjacent sertoli cells near the basement membrane of seminiferous tubules.

SPERMATOGENESIS

Spermatogenesis is the process by which the male gametes called spermatozoa (sperms) are formed from the primitive germ cells (spermatogonia) in the testis. It takes 74 days for the formation of sperm from a primitive germ cell. Throughout the process of spermatogenesis the germ cells have cytoplasmic attachment with sertoli cells. Sertoli cells supply all the necessary materials for spermatogenesis through the cytoplasmic attachment.

Stages of Spermatogenesis

Spermatogenesis is divided into 2 major stages: - 1. Formation of Spermatids; 2.Spermiogenesis

1. FORMATION OF SPERMATIDS

Spermatogenesis begins with the spermatogonia, which contain diploid number of chromosomes (46 no. of chromosomes or 23 pairs of chromosomes). Spermatogonia are a type of stem cells. When they undergo mitosis, some spermatogonia remain near the basement membrane of the seminiferous tubules to serve as reservoir of cells for future mitosis and subsequent sperm production.

The rest of the spermatogonia lose contact with the basement membrane, squeeze through the blood-testis barrier and differentiate into primary spermatocytes which are also diploid.

Each primary spermatocyte soon replicates its DNA and then Meiosis begins. In Meiosis I, homologous pairs of chromosomes line up at the metaphase and crossing over occurs. Then the meiotic spindle pulls one chromosome of each pair towards the opposite poles of the dividing cell during anaphase. The cells formed by Meiosis I are called secondary spermatocytes. Each secondary spermatocyte has 23 chromosomes. In Meiosis II, the chromosomes line up during metaphase and the 2 chromatids of each chromosome separate during anaphase stage. The 4 haploid cells resulting from Meiosis II are called spermatids. A single primary spermatocyte therefore produces 4 spermatids via Meiosis I and II.

2. SPERMIOGENESIS

The final stage of spermatogenesis, spermiogenesis, is the development of haploid spermatids into sperm. No cell division occurs. During this process, spherical spermatids transform into elongated slender sperm. An acrosome forms at the top of the nucleus, which condenses and elongates, a flagellum develops and mitochondria multiply. Sertoli cells dispose off the excess cytoplasm. Finally sperms are released from their connections to sertoli cells, an event known as spermiation. Sperm then enters the lumen of seminiferous tubules. Fluid secreted by the sertoli cells pushes sperm along their way towards the ducts of testis.

STRUCTURE OF SPERM

Sperm is the male reproductive cell developed in the testes. It is also called the spermatozoon. The matured sperm is 60 microns long. Each sperm consists of 4 parts

- Head
- Neck
- Body
- Tail

1. HEAD: Oval/ Triangular in shape, with a length of 3-5 microns, and width of up to 3 microns. The head is formed by a condensed nucleus, a thin cytoplasm and a thin cell membrane. The anterior 2/3rd of the head is like a thick cap and it is called acrosome. It also contains hyaluronidase and proteolytic enzymes which are essential for the sperm to fertilize the ovum.

2. NECK: The head is connected to the body by a short neck. Its anterior end is formed by thick disc shaped anterior end knob, which is also called proximal centriole. The posterior end is formed by another similar structure known as posterior end knob. The neck and body of sperm is together called

middle piece.

3. BODY/ MIDDLE PIECE: It is cylindrical with a length of 5-9 microns and the thickness of 1 micron. The body of the sperm consists of a central core called axial filament covered by thin cytoplasmic capsule. The axial filament starts from posterior end knob of the neck. In the body, the axial filament is surrounded by a closely wound spiral filament consisting of mitochondria.

4. TAIL: It is an elongated cylindrical structure that helps in motility.

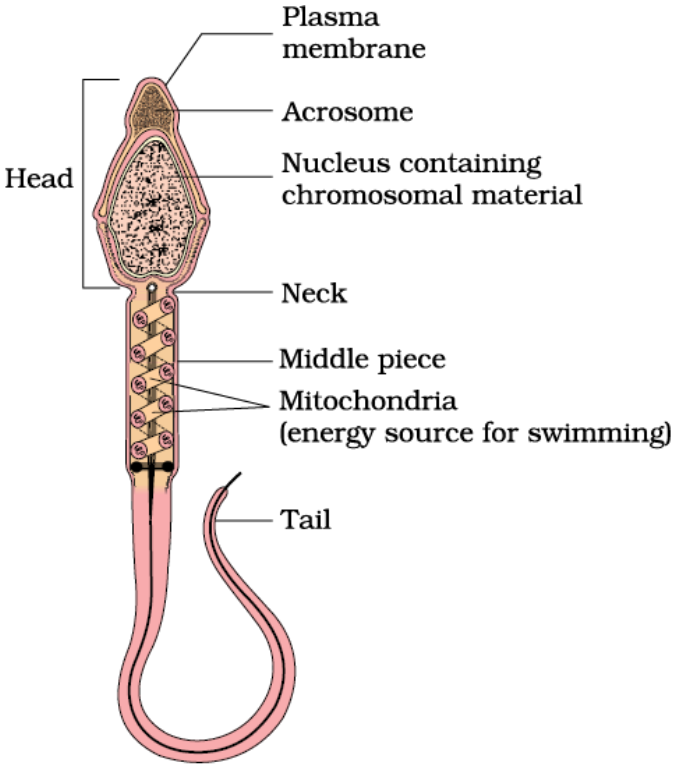

Role of hormones in Spermatogenesis

The hormones necessary for spermatogenesis are:-

1. FSH- responsible for initiation of spermatogenesis, binds with sertoli cells and spermatogonia and induce spermatogonia proliferation, stimulates formation of estrogen and androgen binding protein from the sertoli cells.
2. Testosterone- responsible for the maintenance of spermatogenesis, activity is largely influenced by ABP.
3. Estrogen- formed from testosterone in sertoli cells- necessary for spermatogenesis.
4. LH- it is called Interstitial Cell Stimulating Hormone as it stimulates interstitial cells of Leydig for the secretion of testosterone from them.
5. GH- essential for general metabolic processes in testis and also necessary for proliferation of spermatogonia.
6. Inhibin- secreted by sertoli cells in males and granulose cells of ovarian follicles in females;

plays an important relo in regulation of spermatogenesis by inhibiting FSH secretion through feedback mechanism. FSH secreted from anterior pituitary induces spermatogenesis by stimulating sertoli cells. It also stimulates the secretion of inhibin from sertoli cells. So when spermatogenesis increases, there is simultaneous increase in inhibin secretion. Inhibin inturn acts on anterior pituitary and inhibits secretion of FSH thereby decreasing the speed of spermatogenesis.

7. Activin- exact location of secretion is unknown, but said to be secreted by sertoli cells and Leydig cells; increases the secretion of FSH and accelerates spermatogenesis.

Factors affecting Spermatogenesis:

1. Hormones in spermatogenesis (described before)
2. Increase in body temperature stops spermatogenesis.
3. Infectious diseases like mumps cause degeneration of seminiferous tubules and absence of spermatogenesis.

SEMEN

Semen is a white or grey fluid that contains sperms along with a fluid that contains the secretions of the accessory sex glands. Semen is discharged during sexual act and the process of discharge of semen is called ejaculation.

Seminal vesicles secrete an alkaline, viscous fluid that contains fructose, prostaglandins and clotting proteins that are different from these in blood. The alkaline nature of seminal fluid helps to neutralize the acidic environment of the male urethra and female reproductive tract that would otherwise inactivate and kill sperm. Fructose is used for ATP production by sperm. Prostaglandins contribute to sperm motility and viability and may stimulate the smooth muscle contraction of female reproductive tract. The clotting proteins help semen coagulate after ejaculation. Fluid secreted by seminal vesicles constitutes about 60% of volume of semen.

Prostate gland secretes a milky, slightly acidic fluid that contains a few substances like citric acid used by sperm for ATP production, several proteolytic enzymes like lysozyme, amylase, pepsinogen, hyaluronidase etc. which break down the clotting proteins from seminal vesicles, seminoplasmin, and an antibiotic that can destroy bacteria. Prostate secretions make up to 25% of volume of semen and contribute to sperm motility and viability.

Bulbourethral glands secrete an alkaline fluid into the urethra that protects the passing sperms by neutralizing acids from urine in urethra. They also secrete mucus that lubricates the end of penis and urethra.

The prostate secretion gives semen a milky appearance and fluids from seminal vesicles and

bulbourethral glands give it a stick consistency.

Volume of semen in a typical ejaculation is 2.5- 5ml with 50- 150 million sperm/ml. When the number falls below 20 million/ml, the male is likely to be sterile.

Once ejaculated, liquid semen is coagulated within 5mins due to the presence of clotting proteins from seminal vesicles. After about 10- 20mins, semen re- liquefies because prostate specific antigens and other proteolytic enzymes produced by the prostate gland break down the clot.

FEMALE REPRODUCTIVE SYSTEM

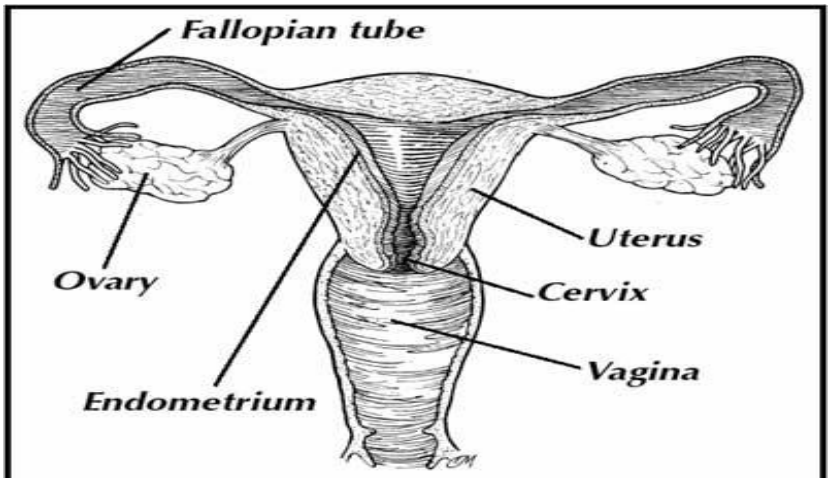

A front view of the female reproductive organs.

The female reproductive system consists of following parts:

1. **Ovaries**. The ovaries are two oval bodies (about 30-40 mm long) located below and behind the uterine tubes. Each ovary is supported by a series of ligaments. The main function of the ovary is to produce eggs (ova) and the female sex hormones, **estrogen** and progesterone. They are attached by a membrane to the uterus and supplied with blood vessels.
2. **The Uterine Tubes**. The uterine tubes consist of the proximal part called oviducts and the distal part called Fallopian tubes. The uterine tubes are attached to the uterus at its upper outer angles. The tubes are lined with cilia and extend to the ovaries. At the distal end each fallopian tube expands into funnel like infundibulum, having the fringe like projections called fimbriae. When ova are released from the ovary they pass down the fallopian tube. Fertilization normally occurs in the Fallopian tube.
3. **The Uterus.** Both oviducts open into a wider tube, the uterus, or womb, which measures about 3 inches in length, 2 inches in width and 1 inch in depth. The uterus consists of a dome-shaped portion, called the fundus, a central tapering portion- the body and a narrow portion opening into

the vagina, called the cervix.

4. **The vagina** is a collapsible muscular tube, about 3 inches long, and capable of great distention. At the lower end of the vagina normally there is a fold of mucous membrane in the virginal state, the hymen, which partially closes the orifice. The vagina receives the seminal fluid, serves as the lower part of the birth canal and acts as an excretory duct for uterine secretions and menstrual flow.
5. **The vulva** is a collective name for female external genitalia. Two folds of skin, the labia majora and the labia minor, enclose the vulva at the entrance to the vagina.
6. **The Bartholin's or vestibular glands** are present on either side of the vaginal orifice, and secrete a lubricating fluid.
7. **The mammary glands,** or breasts, are functionally related to the female reproductive system, since they secrete milk for the nourishment of the young.

OVARY

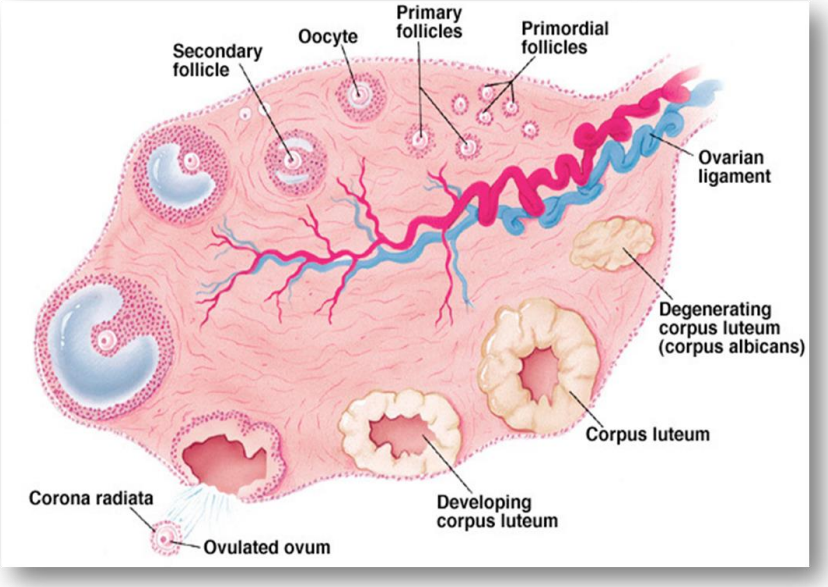

A transverse section of an ovary shows an outer cortex and inner medulla. The medulla contains the connective tissue called stroma, blood vessels and nerve fibers. The cortex is lined by germinal epithelium, below which there are groups of follicles, each enclosing an egg.

The cortex is lined externally by a dense fibrous tissue, the tunica albuginea. Out of many follicles present at birth, only 300 to 400 follicles reach maturity and liberate their ova (ovulation) during the reproductive years of a human female (puberty to menopause). One of the developing follicles (primary follicle, secondary follicle, maturing follicle) form a mature follicle called the Graafian follicle.

GRAAFIAN FOLLICLE

Each Graafian follicle contains the ovum. Immediately surrounding the ovum is a layer of follicle cells, the inner zona pellucida and outer layer of columnar cells, the corona radiata. The follicle contains a fluid filled space called the antrum. The antrum is lined by follicle cells which from two zones, the membrana granulosa and the cumulus oophorus. The Graafian follicle is surrounded by two connective tissue cell layers, the outer theca externa and the inner theca interna. The follicular cells secrete the hormone estrogen which controls the menstrual cycle.

STRUCTURE OF HUMAN OVUM

Human ovum or egg is a round, non motile, haploid female sex cell. It is about 0.15mm in diameter. It has a large centrally located nucleus and dense cytoplasm (ooplasm). The cytoplasm stores food materials required for the entire process of development. The ovum has 4 envelopes,

1. Plasma membrane: Inner most layer.
2. Vitelline membrane: Thin, transparent layer outside the plasma membrane secreted by cytoplasm of ovum.
3. Zona pellucida: Thick, transparent non-cellular layer secreted by follicle cells of the ovary.
4. Corona radiata: Outermost cellular layer of radially elongated follicle cells.

FUNCTIONS OF OVARIES

a. Oogenesis
b. Secretion of sex hormones
c. Menstrual cycle

OOGENESIS

The process of formation of ovum is called oogenesis. It takes place in the Graafian follicle of ovary. The mature follicle contains a diploid primary oocyte at its center. Oogenesis starts during the 7th and 8th month of the fetal life in which the primordial germ cells migrate from the yolk sac to ovaries. A baby girl is born with definite number of primary oocytes already in prophase I in the ovary. Further development of primary oocytes remain suspended till puberty. Oogenesis is completed only after the onset of puberty and only one of 500 diploid cells is stimulated by FSH to mature. So oogenesis is a discontinues process.

Oogenesis is divided into 3 phases. They are,

1. **Phase of multiplication**: The initial steps in egg production. During the phase of multiplication, the germinal epithelial cells of the ovary undergo rapid and repeated mitotic divisions to form groups of diploid egg mother cells called oogonia.

2. **Phase of growth**: During the phase of growth, the oogonia stop mitotic division. These cells grow in size and form the primary oocyte. Thus, about 45000 to 65000 primary oocytes are formed. Other oogonia surround the primary oocyte and transform to follicular epithelium which nourish the primary oocyte.
3. **Phase of maturation**: During the phase of maturation, the diploid primary oocyte in prophase I stage completes Meiosis I and produces 2 unequal haploid cells. The larger cell is called the secondary oocyte and the smaller fragment is called first polar body. The secondary oocyte starts to undergo Meiosis II and cell cycle stops in the Metaphase II stage. At this stage, ovulation occurs and the secondary oocyte is transferred to the fallopian tubule. Meiosis II is restarted only after the entry of sperm during fertilization. Secondary oocyte then undergoes meiosis II to form 2 unequal haploid cells. The larger cell is called ootid and the smaller cell is called second polar body. The first polar body divides into 2 polar bodies. The polar bodies have no role in reproduction. The ootid undergoes further changes and develop into a functional egg cell or ovum.

Even before birth, many oogonia degenerate in a process called atresia. However, a few develop into larger cells called primary oocytes that enter in prophase of Meiosis I during fetal development but do not complete that phase until puberty. During this arrested stage of development each primary oocyte is surrounded by a single layer of follicular cells which is called the primordial follicle. At birth, approx. 2 lakh primordial follicles will be present of these about 40,000 are still present in at puberty and around 500 will mature and ovulate during a woman's reproductive lifetime. The remaining primordial follicles undergo atresia.

MENSTRUAL CYCLE

The cyclic events that that take place in a rhythmic fashion during the reproductive period of woman's life is called menstrual cycle. The menstrual cycle starts at the age of 12-15 yrs, which marks the onset of puberty. The menstrual cycle ceases at the age of 45-50 yrs. The permanent cessation of menstrual cycle in old age is called menopause. The duration of this cycle is usually 28 days. But under normal physiological conditions, it may vary between 25 & 35 days.

During the menstrual cycle, both the ovaries and uterus undergoes several changes. Ovaries help in the development and maturation of ovum and uterus prepares itself for implantation of zygote by proliferation of cells and tissues. Hence, Menstrual cycle is divided into 2 cycles:

1. Ovarian Cycle- ovarian changes
2. Uterine Cycle- endometrial/ uterine changes

OVARIAN CYCLE

Ovarian cycle starts from the 6th day of menstrual cycle. During each ovarian cycle, up to 20 primordial follicles are activated to begin the maturation process, but usually only one reaches full maturity, the remainder regress

The ovarian cycle can be divided into 2 phases: - Follicular Phase and Luteal Phase.

1. Follicular Phase

This phase extends from the 6th day of the menstrual cycle until the time of ovulation, which takes place on the 14th day. During this phase, there is maturation of the ovum.

Each month after puberty till menopause, LH and FSH secreted by the anterior pituitary further stimulate the development of several primordial follicles, cells with primary oocyte surrounded by a single layer of follicular cells. A few primordial follicles start to grow, developing into primary follicles consisting of a primary oocyte surrounded by several layers of cells called granulosa cells. Only one primary follicle which is fast growing develops into a secondary follicle. The remaining primary follicles will degenerate. As primary follicle grows, it forms a clear glycoprotein layer called zona pellucide between the primary oocyte and granulosa cells.

The outermost layer of the granulosa cells gets encircled by a membrane called theca folliculi. As the primary follicle develops into secondary follicle, theca gets divided into theca interna, a highly vascularized internal layer and theca externa, an outer layer of connective tissue cells and collagen fibers. The granulosa cells start to secrete a fluid, which buits up a cavity called the antrum in the center of the secondary follicle. The innermost layer of the granulosa cells become firmly attached to the zona pellucida and form corona radiata.

The secondary follicle still enlarges and forms the mature or Graffian follicle. In this follicle, the diploid oocyte undergoes Meiosis I and produces 2 cells with unequal size. Larger cell with half the number of chromosomes is the secondary oocyte and the smaller cell is the first polar body. The secondary oocyte then starts Meiosis II but stops in the metaphase stage. The graffian follicle ruptures and releases its secondary oocyte, the process called ovulation. The ovum must be fertilized 24- 48 hours after ovulation. If fertilized, it completes its Meiosis II, releases the second polar body and forms the zygote and if not fertilized, it degenerates and goes out through menstrual flow.

2. Luteal Phase

This phase extends between the 15th and the 28th day of the menstrual cycle. Soon after ovulation and rupture of graffian follicle with the release of the mature ovum, the follicle gets filled with blood,.

It is called corpus hemorrhagicum. The blood clots slowly. The follicular cavity closes gradually by the healing of the wound. The blood clot is gradually replaced by a serous fluid containing fibrin which is called corpus luteum. Corpus luteum secretes large quantity of progesterone and it is important for the maintenance of pregnancy. If the ovum gets fertilized, corpus luteum retains till the placenta starts to secrete hormones. If fertilization does not occur, corpus luteum degenerates and gets replaced by a scar called corpus albicans.

UTERINE CYCLE

Uterine cycle or endometrial changes starts from day 1 of menstrual cycle. The endometrium undergoes proliferation and vascularization during this period. Uterine cycle is divided into 3 phases- Menstrual/ Bleeding phase, Proliferative phase and Secretory phase.

Menstrual phase (1st -5th day)

The process of shedding of the uterine lining along with blood and fluid is called menstruation or menstrual bleeding. It lasts for about 4- 5 days and blood loss is usually between 50-150ml. Detached tissues and blood pass through the vagina as the menstrual flow. The day when the bleeding starts is considered to be the 1st day. 2 days before the onset of bleeding, there is sudden reduction in the release of estrogen and progesterone from the ovary which is responsible for menstruation.

Changes in the endometrium during the menstrual phase:-

1. Lack of hormones causes sudden involution of endometrium of uterus, leads to reduction of thickness of endometrium.
2. Vasoconstriction occurs in the endometrium due to prostaglandins released from the tissues of endometrium, which causes necrosis of endometrium due to hypoxia.
3. It causes rupturing of the endometrium and blood oozes out.
4. Superficial layers of the endometrium become desquamated and those tissues with blood in the endometrial cavity initiates the contraction if the uterus, which causes the expulsion of the contents through the vagina to the exterior.

During normal menstruation, the blood clots as soon as it is released into the uterine cavity but the fibrinolysins causes the lysis of clot in the uterine cavity so that the expelled menstrual fluid does not clot. This phase is followed by the proliferative phase.

Proliferative phase (6th -14th day)

It extends usually from the 6th to 14th day of menstrual cycle. It ends with ovulation, i.e., the release of mature ovum from the ovary to uterus. At the end of menstrual phase, only a thin layer of endometrium remains as most of the endometrium is desquamated.

Changes in the endometrium during proliferative phase:

1. Endometrial cells undergo proliferation and increases in thickness; uterine glands start developing, blood vessels reappear and endometrium attains a thickness of about 3-4mm at the end of proliferative phase. Cervical mucus becomes extremely thin.
2. Hormone level increases especially FSH and estrogen. FSH causes or is responsible for oogenesis. But LH is responsible for ovulation. This phase is followed by secretory phase.

Secretory phase (15th -28th day)

This phase extends between the 15th - 28th day, i.e., between the day of ovulation and day when the next menstrual cycle commences. After ovulation, corpus luteum is developed in the ovary. It secretes a large quantity of progesterone, along with a small amount of estrogen. Estrogen causes further proliferation of the cells in uterus, so that the endometrium becomes thicker. Progesterone causes further thickening of endometrium and growth of glands.

Glands of endometrium increases in size and exceeds the thickness of endometrium, deposition of glycogen and lipids in the endometrium increases, new blood vessels appear in the endometrium and blood flow increases.

Secretory phase is the preparatory period during which the uterus prepares for implantation of the ovum. At the end of secretory phase thickness of endometrium will be about 5-6mm. All these uterine changes occur due to the actions of estrogen and progesterone. Estrogen is responsible for the repair of damages endometrium and glands and progesterone is responsible for the secretory functions of the endometrium.

If the ovum gets fertilized during this phase, implanted ovum develops into fetus and further changes of the uterus takes place. If fertilization does not occur, the hormone levels go down and the next menstruation begins.

HORMONAL CHANGES DURING MENSTRUAL CYCLE

Menstrual cycle is regulated by the various hormones secreted by the hypothalamus, anterior pituitary and ovary.

GnRH is secreted by the hypothalamus which occurs during feedback effects of ovarian change or external factors like psychological events which act on the hypothalamus. GnRH stimulates the anterior pituitary which secretes FSH and LH. These hormones act on the ovary and uterus and causes the changes in them. FSH initiates oogenesis and LH initiates ovulation and sustains corpus luteum.

Estrogen and progesterone are secreted by the ovary by the action of FSH and LH on it. Ovarian follicles secrete estrogen and corpus luteum secretes progesterone. Estrogen secretion reaches its peak twice in each cycle- one during follicular phase just before ovulation and one during luteal phase. But progesterone is absent during follicular phase and reaches its peak after ovulation during

the luteal phase. If fertilization does not occur, estrogen and progesterone secreted by corpus luteum will inhibit the action of FSH and LH in the absence of which corpus luteum degenerates and becomes inactive. So progesterone and estrogen becomes absent which by feedback mechanism stimulates hypothalamus for the release of GnRH.

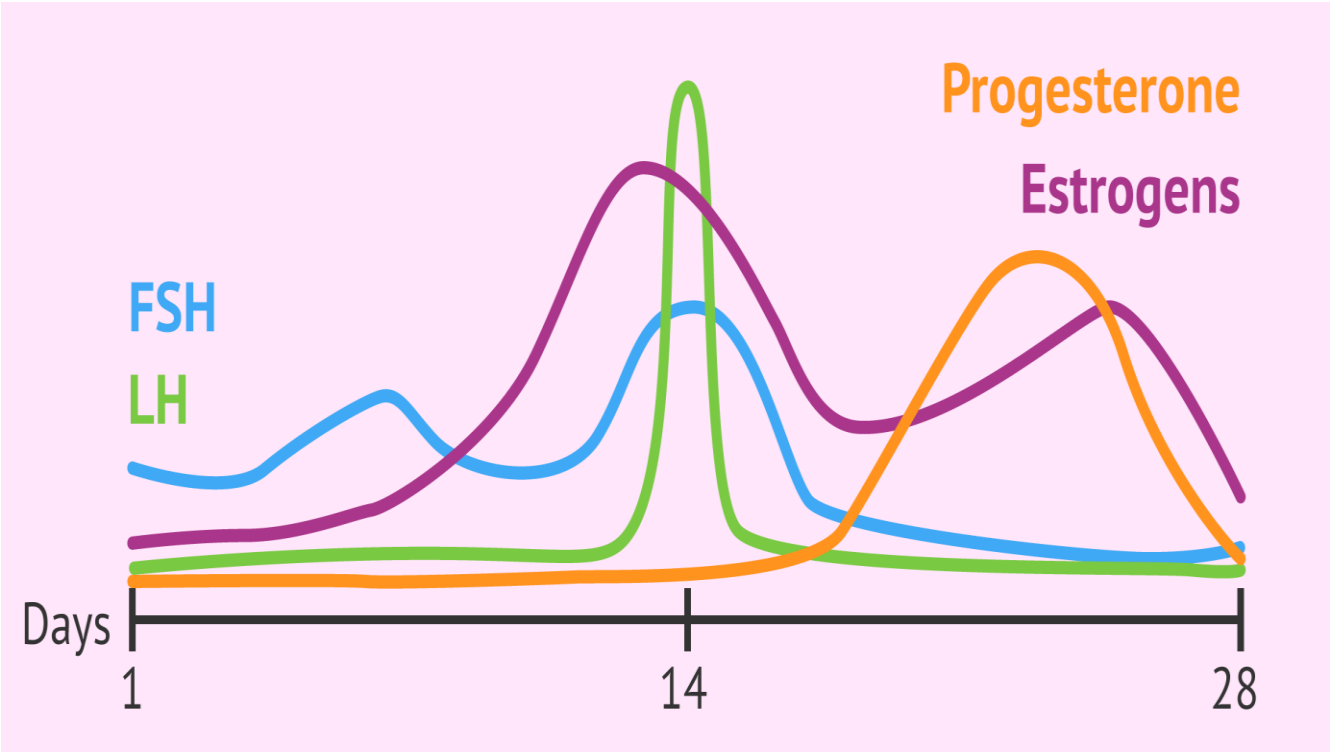

OVULATION

It is the process by which graffian follicle ruptures and the ovum is released into the abdominal cavity. LH is responsible for ovulation. Just before that, large amount of LH is secreted leading to the rupture of graffian follicle.

Tests for Ovulation:

1. Determination of body temperature- increased temperature after ovulation due to the action of progesterone.
2. Determination of hormonal excretion through urine- excretion of metabolites of estrogen and progesterone after ovulation through urine. Products are estrone, estriole and estradiole.
3. Determination of hormonal level in plasma- FSH decreases, LH increases, estrogen increases (at the time of ovulation), progesterone increases after ovulation.
4. Cervical mucus pattern- fern shaped, thin cervical mucus is formed during ovulation. This pattern disappears after ovulation.

FUNCTIONS OF PLACENTA

Placenta is a temporary membraneous muscular organ that develops in females during

pregnancy. It forms a link between mother and child. It is expelled out during parturition.

Functions:

1. Nutritive function- essential nutrients diffuse from mother to fetus.
2. Excretory function- metabolic end products from the fetus diffuses to maternal circulation.
3. Respiratory function- since fetal lungs are non- functional, oxygen necessary for respiration reaches the fetus from the maternal circulation through placenta.
4. Endocrine function- secretion of hormones- hCG (indicative of pregnancy), estrogen, progesterone, hCS (human chorionic somatomammotropin) and relaxin.

PUBERTY

The period of life, when the endocrine and gametogenic function of the gonads have developed for the first time to the point where reproduction is possible, is called puberty. These changes leading to adulthood occurs gradually through a period of life and this period is called adolescents. Age of onset of puberty in female 12 – 15 yrs and in male 11 – 14yrs.

PUBERTAL CHANGES IN MALES:

1. Effect on sex organs- Increases size of penis. Scrotum and testes.
2. Effect on secondary sexual characters-

a. Increase in muscle mass by increasing the synthesis of proteins in muscles.

b. Increases the thickness of bones by causing deposition of calcium; increases the size and strength of bones.

c. Causes broadening of the shoulders.

d. Increases the thickness and melanin pigmentation on skin, enhances secretory actions of the sebaceous glands, increases the secretion of sebum leading to development of acne on the face.

e. Male type of hair distribution.

f. Voice change due to the enlargement and lengthening of larynx and thickening of vocal cords.

g. Increase in BMR; erythropoietic action, increase in RBC and fluid- electrolyte balance.

PUBERTAL CHANGES IN FEMALES:

1. Promotes cellular proliferation and tissue growth in the sexual organs.
2. Promotes growth of ovarian follicles.
3. Enhances the growth and functioning of the uterus and uterine muscles.
4. Enhances the growth and functioning of the fallopian tubules.
5. Increases vaginal layer proliferation, reduces pH of vagina.
6. Female type of hair distribution.
7. Renders softness and smoothness of the skin.

8. Narrowing of the shoulders, broadening of the hips, converging of the thighs, increase in fat deposition in the buttocks and breasts.
9. Production of high- pitched voice.
10. Development of duct system of breasts for lactatory purpose.
11. Increases protein synthesis and fat deposition.

CONTRACEPTION

It is the use of any method or device to prevent pregnancy. The contraceptive methods may be temporary or permanent. Several methods are available for fertility control which is broadly classified into 2 as Temporary method and Permanent method.

Temporary Contraception:

1. Rhythm method (safe period) - based on the time of ovulation. 10th to 18th day of menstrual cycle is considered unsafe as the chances of fertilization are more in this period. The other days are considered to be safe.
2. Oral contraceptives - the drugs taken through mouth to prevent pregnancy. These pills prevent pregnancy by inhibiting the maturation of follicles and ovulation. This leads to the alteration of normal menstrual cycle. Contraceptive pills are of 3 types- Combined pills which contain a moderate dose of estrogen and progesterone, Sequential pills that contain high dose of estrogen with a moderate dose of progesterone and Minipills that contain only low doses of progesterone and are taken throughout the menstrual cycle. These hormones prevent the maturation of ovum, slows down the ovum's progress through the fallopian tubes, thickens cervical mucus and thin the lining of endometrium.
3. Intrauterine Contraceptive Device (IUCD)- prevents the fertilization and implantation of the ovum. The commonly used IUCD is Copper T. The 2 limbs of Copper T blocks the opening of fallopian tube into the uterine cavity, thus preventing sperm entry into the tubes. Copper released from this device prevents implantation of fetus, if it is formed.
4. Mechanical barriers like condoms (for males) and cervical diaphragms (for females).
5. Chemical Method – by using spermicide gels that kill the sperms before entering into the uterus.

Permanent Contraception:

1. Tubectomy- cutting of the fallopian tubes and then ligating the cut ends.
2. Hysterectomy- removal of the uterus.
3. Vasectomy- cutting of the vas deferens and ligating the cut ends.

MAMMARY GLAND AND LACTATION

The breast arises from the surface epithelium as solid column of cells which gradually is

hollowed out to become ducts. These ducts branch to give rise to terminal ductules which in turn lead to the alveoli. At birth, the breast is rudimentary and consists of a tiny nipple from which radiate a few ducts. At puberty, there occurs considerable growth and branching of the duct system which undergoes progressive enlargement due to increased deposition of fat. Between each menstrual period there is hyperaemia of the breasts, increase in intra alveolar stroma with formation of new alveoli; but these changes are transient.

During the first half of pregnancy there is further duct development accompanied by the appearance of many alveoli which form lobules. During the second half of pregnancy the epithelial cells swell with gradual initiation of secretory activity and slow accumulation of milk in the alveolar lumen.

Lactation consists of two separate processes: Milk secretion and milk ejection.

A. MILK SECRETION: It is the synthesis of milk by the alveolar epithelium and its passage into the lumen of the gland. It occurs in two phases: Initiation and maintenance of secretion.

1. Initiation of milk secretion is called Lactogenesis.:

A free flow of milk occurs only some days (1-3) days after the child birth. The in initiation of milk secretion is by low circulating levels of estrogen which activate the lactogenic function of the anterior pituitary mediated by PRL. This effect is due to reduced secretion of PRIH by the hypothalamus

During pregnancy the lactogenic action of estrogen is inhibited by Progesterone. However after child birth the rate of progesterone secretion decreases markedly before the decrease in estrogen occurs, thus allowing the estrogen to perform its lactogenic action

2. Maintenance of milk secretion : It is otherwise known as galactopoiesis. This step is controlled by PRL along with other hormones include GH, TH, Insulin, Adrenal cortical Ovarian Hormones.

B. MILK EJECTION: The discharge of milk from the breast known as milk ejection. More details refer endocrine system (Milk ejection reflex)